



**PATIENT PRESENTING CLINICAL SIGNS**

Goofy Cox History: bweight loss, intermittent soft stool, hematemesis on aug 28 meds: caninsulin 1/2 iu BID Patient is diabetic.

**SPECIES** Abnormal PE/Chem/CBC/UA Results: bplatelets 849, urea 14.5, fPL WNL

Feline

**ULTRASONOGRAPHIC EXAMINATION OF THE ABDOMEN**

**BREED** *Urinary System*

DSH

The **urinary bladder** is moderately distended. In the apical aspect, a 0.41 cm nodule is arising from the luminal surface. The remaining bladder wall is normal in thickness with a smooth mucosal surface. A small amount of suspended, echogenic debris is observed within the lumen. There is no evidence of cystic calculi. The region of the trigone and the proximal urethra, visible to a depth of 1-2 cm, are normal.

**SEX**

Neutered Male

The **left kidney** is normal size (3.61 cm in length); with a slightly irregular shape. The cortex is thickened and hyperechoic. There is poor corticomedullary distinction. Trace pyelectasia is present. There is no evidence of nephroliths or hydroureter. Renal vasculature is normal.

**AGE**

14 years

The **right kidney** is normal size (4.21 cm in length); with a slightly irregular shape. The cortex is thickened and hyperechoic. There is poor corticomedullary distinction. Mild pyelectasia is present (0.19 cm in the longitudinal plane). There is no evidence of nephroliths or hydroureter. Renal vasculature is normal.

**WEIGHT**

11 lbs

*Adrenal Glands*

The region of the **adrenal glands** is evaluated. No obvious pathology is observed.

*Spleen*

The **spleen** is normal in size (0.76 cm in width at the level of the hilus) with a normal capsular contour. There is appropriate echogenicity and echotexture. No focal lesions are observed. Splenic vasculature is normal.

*Liver*

The **liver** is subjectively normal in size with normal contours and structure. There is appropriate echogenicity and echotexture. No overt structural evidence of inflammatory, infiltrative, or regenerative pathology is evident. Vascular and biliary tracts are of normal volume with no evidence of congestion. No pathological hepatic lymphadenopathy observed.

**INTERPRETED BY**

Andrea Nicastro, DVM,  
Diplomate ACVIM  
(Small Animal Internal  
Medicine)

**IMAGING PERFORMED BY**

Kelly Reschny

The **gall bladder** lumen is moderately distended. The wall is thin and smooth. Luminal contents are anechoic. The cystic and common bile ducts are normal/not seen.

**HOSPITAL NAME**

Nelson AH

*Gastrointestinal*

The **gastric lumen** is moderately distended. The gastric wall is normal in thickness with a normal layering pattern. The small intestinal lumen is diffusely dilated with chyme. The small intestinal wall thickness is normal with a normal layering pattern and appropriate mural detail. Discreet masses are not identified. The colonic wall is normal. There is no evidence of an obstructive pattern.

**REFERRING VET**

Dr. Anderson

*Pancreas*

A portion of the **pancreas** is obscured by the gastric distention. In the visualized portion, no obvious pathology is observed.

**INVOICE**

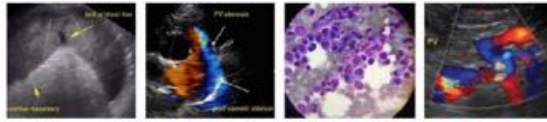
11567

*Free Abdomen*

There is no evidence of free fluid. The abdominal **lymph nodes** are normal/not visible.

**DATE**

9.1.22



**PATIENT**      **ULTRASONOGRAPHIC FINDINGS**

Goofy Cox      **Primary Findings**

**SPECIES**

Feline

- Bilateral chronic nephropathy. The bilateral pyelectasia may be secondary to age-related remodeling, pyelonephritis, PU/PD (if applicable), or some combination thereof.
- The nodule in the apical region of the urinary bladder may represent a benign polyp, inflammatory focus or emerging tumor.

**BREED**

DSH

**INTERPRETATION OF THE FINDINGS & FURTHER RECOMMENDATIONS**

Regarding the GI signs, consider the following:

**SEX**

Neutered Male

1. A repeat ultrasound of the GI tract when the patient is fasted, to better evaluate for underlying pathology.
2. Malabsorption panel including serum cobalamin and folate, TLI and PLI (send to Texas A&M).
3. A fecal evaluation for ova and Giardia is recommended.
4. Prophylactic deworming with Fenbendazole
5. 6-week hydrolyzed protein limited antigen diet trial
6. Consider empirical treatment for small intestinal bacterial overgrowth with a 2-4-week course of Tylosin.
7. Also consider initiation of a probiotic with a high colony count (i.e., Provable Forte)
8. Depending on the results of the above diagnostic/therapeutics, GI biopsies (i.e., endoscopic, or surgical) may be necessary to get a definitive diagnosis.

**AGE**

14 years

**WEIGHT**

11 lbs

Regarding the urinary bladder wall lesion, consider a urine BRAF test to further assess for lower urinary tract neoplasia. Alternatively, consider a repeat ultrasound in 3-4 weeks to assess for progression.

**INTERPRETED BY**

Andrea Nicastro, DVM,  
Diplomate ACVIM  
(Small Animal Internal  
Medicine)

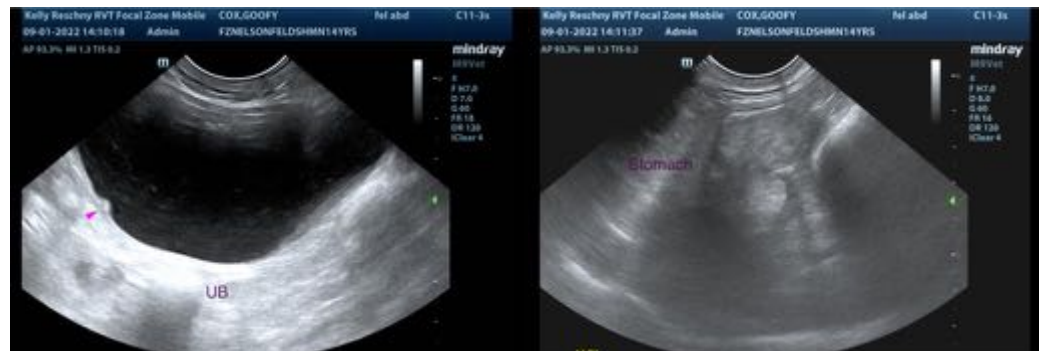Given the sonographic renal changes, serial monitoring (i.e., every 3-4 months) of the patient's renal values and urine specific gravity is recommended to assess for the development of renal dysfunction.

**IMAGING PERFORMED BY**

Kelly Reschny

**HOSPITAL NAME**

Nelson AH



**REFERRING VET**

Dr. Anderson

**INVOICE**

11567

**DATE**

9.1.22



**PATIENT**

Goofy Cox

**SPECIES**

Feline

**BREED**

DSH

**SEX**

Neutered Male

**AGE**

14 years

**WEIGHT**

11 lbs

**INTERPRETED BY**

Andrea Nicastro, DVM,  
Diplomate ACVIM  
(Small Animal Internal  
Medicine)

**IMAGING  
PERFORMED BY**

Kelly Reschny

**HOSPITAL NAME**

Nelson AH

**REFERRING VET**

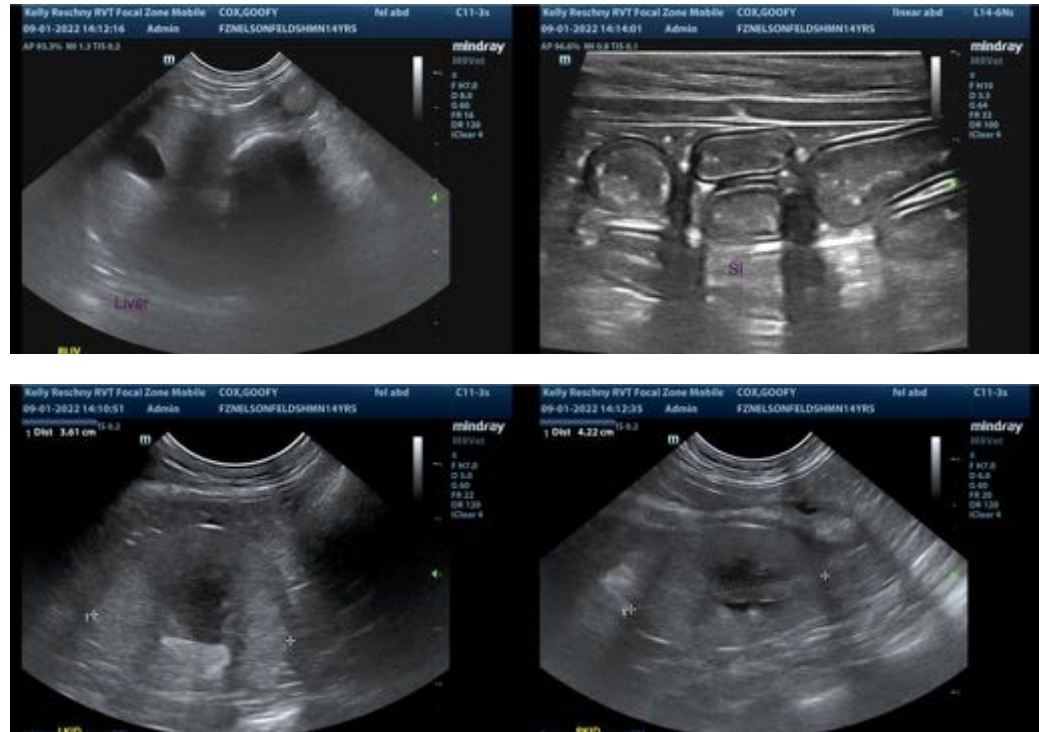
Dr. Anderson

**INVOICE**

11567

**DATE**

9.1.22



The information and recommendations provided are based on the images presented by the referring veterinarian/sonographer. No evaluation can be communicated regarding pathology that was not visible in the image/video clips provided.

Thank you for this referral. If the clinical or image interpretation does not parallel your findings or if I can be of any further assistance, please contact me.

**Andrea Nicastro, MPH, DVM, Diplomate DACVIM (Small Animal Internal Medicine)**  
info@SonoPath.com